

COULD THE ACUTE *Strongyloides venezuelensis* INFECTION CAUSE NON-REVERSIBLE HOST MORPHOLOGICAL CHANGES?

Recebido em: 02/06/2023

Aceito em: 30/09/2024

DOI: 10.25110/arqsaude.v28i2.2024-10351



Anna Júlia Fernandes Figueiredo¹
Flávia da Silva Resende²
Vitor Luís Tenório Mati³
Luana Anjos-Ramos⁴

ABSTRACT: Although research has investigated the host-parasite relationship in *Strongyloides venezuelensis* infection in the scope of its immunological implications, the morphological consequences of this response for the host organism are yet to be explored. Our objective was to perform an organ morphometric analysis in Wistar rats infected with the intestinal parasite *Strongyloides venezuelensis* compared with infected rats treated with ivermectin. Twenty-six animals composed three groups: control (non-infected), infected (infected with 2,000 *Strongyloides venezuelensis* larvae), and infected treated (infected with 2,000 *Strongyloides venezuelensis* larvae and treated with ivermectin). All rodents were killed 21 days after infection and morphometric analysis of different organs was performed. The results showed significantly higher body and fecal weight in the infected-treated group. The weight of the small intestine increased considerably in the infected group and decreased in the infected-treated group. Pancreas, right kidney, and heart volume increased in the infected group compared with the control group. Despite treatment, the volumes of the stomach, brain, and left kidney increased in both the infected groups compared with the control group indicating the possibility of non-reversible host morphological adaptations. *S. venezuelensis* infection can augment both, volume and weight of organs – not necessarily related to the *Strongyloides* expulsion process – even if the acute infection had been in remission. A potential explanation for these host adaptations, including the occurrence of organ plasticity, are briefly discussed. The following steps encompass a histological analysis to verify the occurrence of

¹ Bachelor degree in Biomedicine. Laboratory of Scientific Acupuncture and Infectious-Morphological Investigations (LACIIM), Institute of Biological and Health Sciences, Universidade Federal de Mato Grosso, Barra do Garças – Mato Grosso Brazil.

E-mail: annajff@hotmail.com ORCID: <https://orcid.org/0000-0002-9817-1451>

² Master in Immunology and Parasitology. Laboratory of Bioactive Compounds Studies Group; Basic and Applied Immune and Parasitology Graduate Program, Universidade Federal de Mato Grosso, Barra do Garças – Mato Grosso Brazil.

E-mail: fresende94@gmail.com ORCID: <https://orcid.org/0000-0001-5018-0642>

³ Doctor in Science, emphasis in Parasitology. Department of Medicine, Universidade Federal de Lavras – Minas Gerais Brazil.

E-mail: vitor.mati@ufla.br ORCID: <https://orcid.org/0000-0001-9976-6214>

⁴ Doctor in Science, emphasis in Parasitology. Laboratory of Scientific Acupuncture and Infectious-Morphological Investigations (LACIIM), Institute of Biological and Health Sciences, Universidade Federal de Mato Grosso, Barra do Garças – Mato Grosso Brazil.

E-mail: luana.ramos@ufmt.br ORCID: <https://orcid.org/0000-0002-2754-7722>

hypertrophy/hyperplasia and observe if such morphological alterations remain after infection.

KEYWORDS: *Strongyloidiasis*; Morphometry; Host-parasite relationship; *Strongyloides spp.*

A INFEÇÃO AGUDA POR *Strongyloides venezuelensis* PODE CAUSAR ALTERAÇÕES MORFOLÓGICAS IRREVERSÍVEIS NO HOSPEDEIRO?

RESUMO: Embora pesquisas tenham investigado a relação parasita-hospedeiro na infecção por *Strongyloides venezuelensis* no âmbito de suas implicações imunológicas, as consequências morfológicas dessa resposta para o organismo hospedeiro ainda precisam ser exploradas. Nosso objetivo foi realizar uma análise morfométrica de órgãos em ratos Wistar infectados com o parasito intestinal *Strongyloides venezuelensis* em comparação com ratos infectados tratados com ivermectina. Vinte e seis animais compuseram três grupos: controle (não infectados), infectados (infectados com 2.000 larvas de *Strongyloides venezuelensis*) e tratados infectados (infectados com 2.000 larvas de *Strongyloides venezuelensis* e tratados com ivermectina). Todos os roedores foram sacrificados 21 dias após a infecção e a análise morfométrica de diferentes órgãos foi realizada. Os resultados mostraram peso corporal e fecal significativamente maior no grupo tratado infectado. O peso do intestino delgado aumentou consideravelmente no grupo infectado e diminuiu no grupo infectado tratado. O volume do pâncreas, rim direito e coração aumentou no grupo infectado em comparação com o grupo controle. Apesar do tratamento, os volumes do estômago, cérebro e rim esquerdo aumentaram em ambos os grupos infectados em comparação com o grupo controle, indicando a possibilidade de adaptações morfológicas não reversíveis do hospedeiro. A infecção por *S. venezuelensis* pode aumentar tanto o volume quanto o peso dos órgãos – não necessariamente relacionado ao processo de expulsão de *Strongyloides* – mesmo que a infecção aguda estivesse em remissão. Uma possível explicação para essas adaptações do hospedeiro, incluindo a ocorrência de plasticidade de órgãos, é brevemente discutida. As etapas a seguir compreendem uma análise histológica para verificar a ocorrência de hipertrofia/hiperplasia e observar se tais alterações morfológicas permanecem após a infecção.

PALAVRAS-CHAVE: Estrongiloidíase; Morfometria; Relação parasita-hospedeiro; *Strongyloides spp.*

¿PUEDE LA INFECCIÓN AGUDA POR *Strongyloides venezuelensis* PROVOCAR CAMBIOS MORFOLÓGICOS IRREVERSIBLES EN EL HUÉSPED?

RESUMEN: Aunque se ha investigado la relación parásito-hospedador en la infección por *Strongyloides venezuelensis* en el contexto de sus implicaciones inmunológicas, aún no se han explorado las consecuencias morfológicas de esta respuesta para el organismo hospedador. Nuestro objetivo fue realizar un análisis morfométrico de los órganos de ratas Wistar infectadas con el parásito intestinal *Strongyloides venezuelensis* en comparación con ratas infectadas tratadas con ivermectina. Veintiséis

animales se distribuyeron en tres grupos: control (no infectados), infectados (infectados con 2000 larvas de *Strongyloides venezuelensis*) e infectados tratados (infectados con 2000 larvas de *Strongyloides venezuelensis* y tratados con ivermectina). Todos los roedores fueron sacrificados 21 días después de la infección y se realizaron análisis morfométricos de diferentes órganos. Los resultados mostraron pesos corporales y fecales significativamente superiores en el grupo infectado-tratado. El peso del intestino delgado aumentó considerablemente en el grupo derecho y el corazón aumentó en el grupo infectado en comparación con el grupo de control. A pesar del tratamiento, los volúmenes del estómago, el cerebro y el riñón izquierdo aumentaron en ambos grupos infectados en comparación con el grupo de control, lo que indica la posibilidad de adaptaciones morfológicas no reversibles del hospedador. La infección por *S. venezuelensis* puede aumentar tanto el volumen como el peso de los órganos, que no están necesariamente relacionados con el proceso de expulsión de *Strongyloides*, incluso si la infección aguda estaba en remisión. Se debate brevemente una posible explicación de estas adaptaciones del hospedador, incluida la ocurrencia de plasticidad de los órganos. Los pasos siguientes comprenden un análisis histológico para verificar la aparición de hipertrofia o hiperplasia y observar si estas alteraciones morfológicas persisten tras la infección.

PALABRAS CLAVE: *Strongyloidosis*; Morfometría; Relación parásito-hospedador. *Strongyloides* spp.

1. INTRODUCTION

In humans, strongyloidiasis is an intestinal neglected parasitosis mainly caused by the parasites *Strongyloides stercoralis* (BEKNAZAROVA; WHILEY; ROSS, 2016; BELINELO *et al.*, 2009; ZAHA, O; HIRATA, T, KINJO, F; SAITO, 2000) and *Strongyloides fuelleborni* (BETHONY *et al.*, 2006; SIDDIQUI; BERK, 2001). The first species is responsible for the vast majority of cases and can survive for decades in the host's small intestine by taking advantage of the weakened immune system (CABRAL *et al.*, 2015), causing hyperinfection and spread of the disease. *Strongyloides* is a genus belonging to the Nematoda phylum, ranging approximately 60 species (VINEY; KIKUCHI, 2017). Nearly 30 to 100 million people are infected with Strongyloidiasis around the world, mostly in tropical and subtropical regions (AHMAD *et al.*, 2013; BELINELO *et al.*, 2009; THOMAS B. NUTMAN, 2017). In each reproductive cycle, *Strongyloides* larvae L3 penetrate the host's skin, oral or gastric mucosa, reaching the bloodstream – it triggers the host's immune response (IRIEMENAM *et al.*, 2010) – and pulmonary circulation, covering a migration road until the small intestine. The larvae then

move to the pharynx, subsequently swallowing to continue the cycle. In the small intestine, adult females oviposit eggs that will hatch in the intestinal lumen and eliminate with feces, thus initiating a new cycle (OLSEN *et al.*, 2009). In cases of disease spread, ectopic organs are also affected, such as the brain and kidneys (REYES *et al.*, 2017; ROSSETTO *et al.*, 2010). Laboratory studies of *S. stercoralis* infection require the use of species that infect susceptible hosts (e.g., nonhuman primates) to investigate the mechanisms of the parasite-host relationship (BEKNAZAROVA; WHILEY; ROSS, 2016). Thus, the rodent species such as *Strongyloides ratti* and *S. venezuelensis* have been described as the main models of experimental infections in laboratory rats since their cycles are similar to the that of the *S. stercoralis* species (VINEY; KIKUCHI, 2017). Ivermectin has been the most effective antiparasitic drug for Strongyloidiasis, and can be administrated orally or parenterally in more severe cases (BOGAN; MCKELLAR, 1988; SATOU *et al.*, 2001).

Alterations in the organs involved in the route of this parasite have been described in the scientific literature (MARRA *et al.*, 2011a; TAKAMURE, 1995). Some pathological processes, including parasitic infections, require an intense immediate response from the body to solve or contain more serious damage. Thus, organs and systems involved in this process may undergo functional changes that can result in permanent anatomical changes. Anatomical alterations are known to be always accompanied by physiological alterations, and vice versa (SIECK, 2019). Thus, hypertrophy or hyperplasia of overloaded cells can occur in different pathological processes (GIUNCHETTI *et al.*, 2008). Consequently, after solving the problem, the sequelae are gradually perceived, and adaptations are detected. In this sense, anatomical landmarks may be left as clues of what happened previously, proving the effort used to fight infection.

At the same time, parasitosis can affect organs and systems that are not always directly involved with the infection (SOUSA-RIBEIRO; TAVORE; ANJOS-RAMOS, 2019). Although much is known about the histopathology and immune response to *S. venezuelensis* infection, anatomical changes, in general, have not been studied so far. Therefore, our focus in this study turns over to the host of this helminthiasis and the possible morphological changes associated with the infection by *S. venezuelensis*, that even being an attempt to favour the immunological defence - it may evolve to pathophysiological conditions that in the long-term harm the host. This work contributes

to his field of research with a different view of the infection *Strongyloides venezuelensis*, based on the morphological adaptations of the host to the infection, even in an acute way. Changing the point of view, it is expected to encourage new research possibilities in the host-parasite relationship, expanding the understanding of an infection that is so important and at the same time with many questions to be answered.

2. MATERIALS AND METHODS

2.1 Experimental design

The study included twenty-six adult Wistar rats (*Rattus norvegicus*) weighing between 361 and 523g. We chose male rats because females may be more resistant to the parasite; in addition, the oviposition period would interfere due to the amount of sex hormone increasing immunological responses and helminth-resistant genes (RIVERO *et al.*, 2002).

The rats were maintained in the Laboratory of Scientific Acupuncture and Infectious-Morphological Investigations (LACIIM) under controlled conditions of light, temperature, humidity, and standardization of 500 ml of water and 250 grams of feed.

The project was approved by the Ethics Committee on the Use of Animals of Araguaia (ECUA – Araguaia) of the Federal University of the State of Mato Grosso (no. 23108.089755/2019-61).

The animals were divided into three groups: Control (not infected; n = 10); Infected (submitted to *S. venezuelensis* infection; n = 10), and Infected treated (submitted to *S. venezuelensis* infection and treated with ivermectin; n = 6).

2.2 Deworming

Initially, all animals were dewormed with 1.5 mL of 1% Ivermectin (Mogimec™) diluted into 700 mL of water, at least 15 days before infection. After 7 days, we applied the HPJ (Hoffman, Pons, and Janer) or spontaneous sedimentation method and waited 25 hours to check for the presence of eggs. For this purpose, we used 2 grams of faeces macerated with a pestle in filtered water, subsequently straining the content and removing one drop with a Pasteur pipette for visualization under the COLEMAN™ binocular microscope N107.

2.3 Parasitism

The absence of parasites allowed to perform the infection. We obtained the *S. venezuelensis* strain from the Parasitology Department of the Federal University of Minas Gerais (UFMG), where they had been maintained since 1987 by Dr. Alan Lane de Melo, who kindly donated it to the LACIIM at UFMT – University Campus of Araguaia, kept in gerbils (*Meriones unguiculatus*).

Unlike rats, gerbils do not eliminate parasite larvae from the gastrointestinal tract, thus justifying their being often used in parasitological experiments (MENDONÇA *et al.*, 2019).

We applied the Baermann-Moraes method (HERNÁNDEZ-CHAVARÍA; AVENDAÑO, 2001; KNOPP *et al.*, 2014) to the infection process using photo-hydrothermotropism to separate the larvae. Coprocultures of the infected gerbils were performed after placing the species in anticoprophagic boxes and collecting their feces to be mixed with water and vermiculite. Subsequently, we stored them in a BOD DIGITAL CienlaB™ incubator at 27 Celsius degrees (adequate temperature for eggs with non-infective larvae L1 / rhabditoids to be transformed into infective larvae L3/filarioids) for 72 hours.

After this period, we covered the species with gauze over a sieve and submerged them in warm water (approx. 43° Celsius degrees) using a funnel attached to a test tube with a rubber, which allowed the larvae to pass to the tube's bottom. The liquid remained in contact with light and warm water for approximately three hours. After this period, the gauze with the feces and vermiculite was discarded, the supernatant removed and the liquid containing the larvae were transferred to a falcon, with water up to the measurement of 15 ml. It was followed by three washing procedures in the centrifuge at 3,000 rotations per minute for three minutes. The last washing used filtered water.

At the end of the procedure, we collected 5 ml of the solution with L3 larvae and removed 5 ml for the infection procedure. In addition, 20 microliters were needed to analyze the slide microscope with a drop of Lugol 2% NOVO PROV™ and coverslip. We used a 4x lens to visualize the larvae and counted them to calculate the amount of solution containing L3 (infecting larva) required to apply approximately 2,000 larvae to the animal. The rats were then inoculated with L3.

2.4 Physiological parameters

We assessed water consumption, feed, measurement of feces weight, and body weight from day 0 (0 dpi (days post-infection)) to 21st day (21st dpi) analyzing the measurements every three days.

Figure 1 shows the calculation of body weight gain according to the following formula: final weight (fw; 21st day) – start weight (sw; 0 days). For the feces weight gain, we calculated the fw - sw to obtain the weight in the 21st and 0 dpi.

2.5 Morphometry

All rats were submitted to a lethal dose (2x the usual dose) of anesthetics Ketamine (Cetamin™) and Xylazine (Calmiun™) for death at 21 days after infection by deepening anesthesia.

The following calculations were used for euthanasia:

Ketamine	Xylazine
0,75 ----- 1000g	0,50 ----- 1000g
X ----- Weight of animal	X ----- Weight of animal

For the application, X was multiplied by 2 for duplicate injection.

We then performed laparotomy and thoracotomy procedures (opening of the abdominal and thoracic cavity, respectively) to remove the organs, in addition to cranial opening for brain removal.

An electronic scale (Bioscale™ BL-2200AS-BI) obtained the weight of bodies (in grams) and the organs (g). We analyzed the spleen, heart, brain, stomach, liver, small intestine, pancreas, lung, right kidney, left kidney, and thymus using a measuring tape. In addition to the measurement of the small intestine (m) length, the length, width, and thickness (in millimeters/mm) of the following organs were measured on a digital electronic caliper: spleen, heart, brain, stomach, right kidney, and left kidney.

2.5 Analysing the volume of the organs

We applied the formula $x = \frac{4}{3} \times \text{Pi} \times (A \times X \times x)$, elaborated by Araújo and collaborators (31), to analyze the organ volume, in which A is the length radius value, B

is the width radius value, and C is the thickness radius value. The calculation used the P value of 3.14. Measurements were in cm^3 .

2.6 Data analysis

The statistical analyses were performed using the ANOVA oneway™ with Tukey post-test. PRISM™ was applied to assemble the graphs with their respective means and standard deviations. The significance level was $p < 0.05$ for all groups.).

3. RESULTS

None of the rats had spontaneous death during the experiment.

Figure 1A describes the body weight gain showing an increase in the physiological parameters of both the Infected and Infected/treated groups (68.83 ± 11.26 and 47.20 ± 21.39 , respectively) concerning the Control group (-5.37 ± 11.76), which had a loss of body weight and feces weight. The chart also describes the feces weight gain (fig 1B), which showed an increase in the Infected and Infected/treated groups as well (3.50 ± 1.77 and 1.78 ± 4.24 , respectively) compared with the Control group (-5.345 ± 1.144).

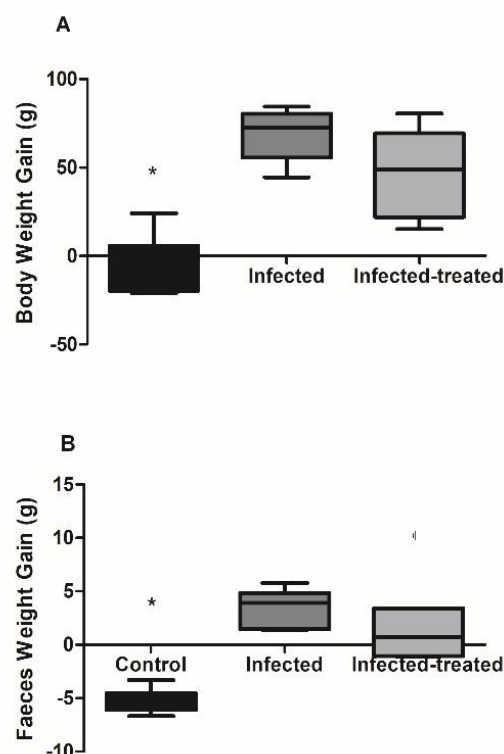


Figure 1: Physiological parameters: body (A) and faecal (B) weight gain in the Control, Infected and Infected-treated groups. * vs other groups. The data were expressed in mean \pm SD (ANOVA $p < 0.05$).

Font: Prepared by the authors (2020).

Figure 2 refers to the relative weight of the Small Intestine (B), Pancreas (C), and Right Kidney (D). Although the relative weight was and analyzed for other organs, the figure shows only the significant results. The small intestine weight of the animals in the Infected/treated group was lower than that of the Infected group (0.028 ± 0.002 and 0.033 ± 0.003 , respectively). In contrast, the relative weights of the pancreas (0.00223 ± 0.00099) and right kidney (0.0037 ± 0.0004) were higher in the Infected group than in the Control group (0.00114 ± 0.000379 and 0.0029 ± 0.0006 , respectively).

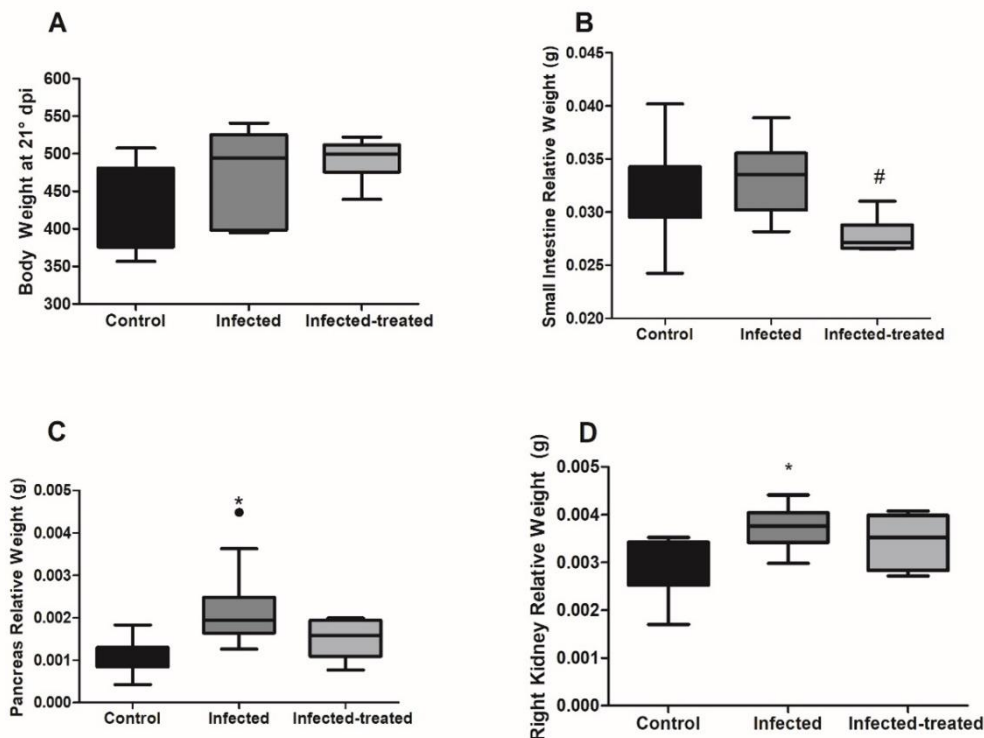


Figure 2: Relative weight of organ's: body weight at 21st dpi (A) and relative weight of Small Intestine (B), Pancreas (C), Right Kidney (D) in the Control, Infected and Infected-treated groups. # vs Infected group; * vs Control group. The data were expressed in mean \pm SD (ANOVA $p < 0.05$).

Font: Prepared by the authors (2020).

In Figure 3, the measurement of the length, width, and thickness of the organs allowed us to observe their volume. Despite the treatment, the volumes of the stomach (3122.84 ± 413.84 , Infected; 2755.86 ± 430.38 , Infected/treated – figure 3C), brain (1089.9 ± 165.5 , Infected; 1046.89 ± 147.96 , Infected/treated – figure 3D), and left kidney (1239.7 ± 152.3 , Infected; 1256.5 ± 53.5 , Infected/treated – figure 3F) were higher in the infected animals than in the Control group (2049.8 ± 297.3 , 743.98 ± 255.47 and 1019.9 ± 199.2 , respectively), none of the animals was infected. Figure 3B shows an

increase in the heart volume in the Infected group (1083.25 ± 110.63) vs the Control group (902.58 ± 155.95).

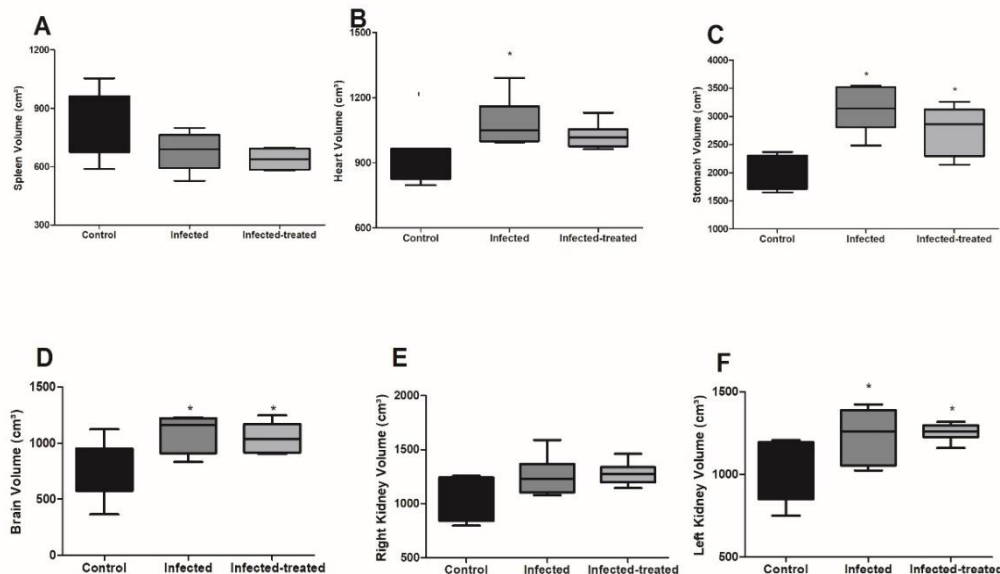


Figure 3: Organ's Volume: the organ's volume in cm³ of Spleen (A), Heart (B), Stomach (C), Brain (D), Right Kidney (E) and Left Kidney (F) in the Control, Infected and Infected-treated groups. * vs Control group. The data were expressed in mean \pm SD (ANOVA $p < 0.05$).

Font: Prepared by the authors (2020).

4. DISCUSSION

Strongyloidiasis is an important parasitosis widely studied in the context of *S. venezuelensis* experimental infection in rodents, especially for its immunological aspect (BRELOER; ABRAHAM, 2017; YASUDA; MATSUMOTO; NAKANISHI, 2014). However, the implications of the host-parasite relationship in the host's morphology have been neglected. In fact, this is the first study to demonstrate potential effects of *Strongyloides* spp. on the volume and weight of the host's organs, which agrees with the current knowledge that the host's adaptations at an immunological and physiological level in the face of infection can also be expressed as identifiable anatomical changes in morphometry, a branch of morphology defined as a quantitative analysis of biological forms (UTKUALP; ERCAN, 2015).

In this context, volumetric analysis of organs can be applied for comparative purposes to verify shape changes related to pathological processes – such as the use of hand volume to consider the presence of cardiomegaly. It was only very recently that researchers have started to dispute this type of comparative measure (AMPANOZI *et al.*,

2018), which reinforces the need to perform morphometric analyses even in known experimental models, such as infection by *S. venezuelensis* in rats.

Therefore, we analyzed the volume of the organs to complete the morphological analysis. Despite the treatment, the infection contributed to enhancing the weight of feces and the body itself, which can be explained by the lower intestinal transit previously described (ANJOS-RAMOS *et al.*, 2016a). Clinically, these findings may be related to the manifestations described by Nutman (THOMAS B. NUTMAN, 2017) observed in patients with chronic hyperinfection, causing symptoms such as diarrhea, abdominal pain, vomiting, swelling in the abdominal region, and inflammations in the gastrointestinal tract.

Interestingly, the infection increased the relative weight of the pancreas and right kidney compared to the Control group, while the ivermectin treatment reduced the small intestine's relative weight compared with the Infected group.

In this context, the literature describes fecal abnormality, nausea, and vomiting under high ivermectin doses (GUZZO *et al.*, 2002; MENDONÇA *et al.*, 2019), therefore, since the ivermectin was orally administrated, gastrointestinal effects were expected (CANGA *et al.*, 2008). According to Mendonça and collaborators (MENDONÇA *et al.*, 2019), ivermectin administration in uninfected animals alone for prolonged periods can affect the small intestine morphology. Similarly, researchers (TRAILOVIĆ; NEDELJKOVIĆ, 2011) have showed that ileum tonus augment when submitted to high concentrations of this drug. Taken together, these results corroborate our findings and demonstrate that ivermectin itself can present a direct gastrointestinal effect. Considering its common use to treat parasite intestinal infection, the effects of ivermectin should be considered alongside the parasite effects.

Considering that both the stomach and heart remain on the route of larval migration until becoming lodged in the small intestine, their increased volume is likely to be related to both conditions previously described - gastrointestinal transit alterations, maintaining the larvae longer in the gastric environment (ANJOS-RAMOS *et al.*, 2016b) and enhancing blood pressure, implicating on a compensatory heart hypertrophy responding to the augmented flow (SOUSA-RIBEIRO; TAVORE; ANJOS-RAMOS, 2019).

Even though previous works have described some brain implications of *S. stercorallis* hyperinfection (OKTAR; OZER; DEMIRTAS, 2020; REYES *et al.*, 2017),

studies using Lewis rats infected with *S. venezuelensis* could not find any larvae on cerebrum tissue (MARRA *et al.*, 2011b). Thus, brain morphometric alterations possibly represent an indirect and remote effect of *S. venezuelensis* infection. These probable indirect effects related to the infection process were also observed in other organs, as therein demonstrated, including heart, kidney and pancreas. They may be related, for example, to neuroendocrine and, or immunophysiology changes leading to organ plasticity. Such mechanism behind these anatomical alterations need be further investigated. Anyway, the efforts to suppress this important infection seems to implicate all host organism, with noticeable modifications in the very acute infection process.

Feldmeyer *et al.* (AMPANOZI *et al.*, 2018) claim that parasitism can alter the physiology, morphology, life history, and behavior of the host. In our study, despite the rapid resolution of the infection in rats, we observed that the organism as a whole is committed to combating the infection, resulting in very rapid morphological changes concerning other pathophysiological processes, like cardiomyopathic syndromes (TRACHTENBERG; HARE, 2017). Such uncommonly fast morphological response is described for the first time in *S. venezuelensis* infection in rats, contributing to understanding the host-parasite interactions and their short and long-term consequences.

Interestingly, the high and left kidneys were differently affected by the *S. venezuelensis* infection. This result agrees with and may be explained by asymmetry host implications on propagation and transmission of parasites (MØLLER, 2006). Taking together with results described above - high blood pressure cardiac hypertrophy – it is possible that heart right ventricle overloaded and pulmonary hypertension corroborated this finds.

Organism phenotype results from the interaction between genotype and external factors that modulate genotype expression. In this context, parasites can cause shifts in the expression of host phenotypic, physiological, and behavioral traits in the host. In vertebrates, such an influence is often proportional to the infection severity (POULIN; THOMAS, 1999). Until then, morphological implications of *S. venezuelensis* infection on host phenotype have not been described. For a better understanding of these findings, histological, physiological, and behavioral implications should be considered in further experiments.

Since the host-parasite relationship can evolve to genomic and consequently evolutionary adaptations (BEN SHELDON, 1998; BETTS *et al.*, 2018; BUCK;

WEINSTEIN; YOUNG, 2018), and some helminths are even associated with cancer development later in life (VENNERVALD; POLMAN, 2009), further studies should perform histological analyses to verify the occurrence of hypertrophy or hyperplasia in the cells of the organs and observe whether and for how long such morphological alterations remain after the infection period.

From a broader perspective, evolutionary morphological adaptations are observed in response to infections that over time have come to commensalism (DREW; STEVENS; KING, 2021). Would it be possible for the host's response to parasitic infection by *Strongyloides* spp. to cause important morphological changes to adapt to the physiological requirements generated by this parasite, which will be perpetuated by natural selection in future generations of hosts? Maybe our research, proposing looking at this infection in another way, is a starting point for an unexplored research field in experimental strongyloidiasis.

5. CONCLUSION

In conclusion, the combination of our results demonstrates that *S. venezuelensis* infection can increase both the weight and volume of the organs suggesting host organ plasticity – not necessarily related to the *Strongyloides* expulsion process – even upon acute infection remission. Thus, in fact, *S. venezuelensis* infection can be associated with morphological changes found in the host, possibly in the sense of favouring the immune defence. The extent to which these changes are involved in the long-term pathophysiology of this infection needs further investigation. The following steps encompass histopathology and cellular biology studies, including genetic and epigenetic evaluations, aiming to observe whether and for how long such morphological alterations remain after the infection period.

Confirming these findings in another experimental models, it's could indirectly impact the way the infection is seen in humans, understanding that even if it resolves quickly, the host can take some morphological changes in the long term, resulting in damage to their health and bringing possible social consequences. Also, it is expected that those outcomes to encourage morphological research of the host-parasite relationship, focus on the host, expanding the understanding of *Strongyloides* infection.

The limitations of this research are related to the experimental model, commonly used to study this infection, but which does not completely mimic the infection in humans,

since in rodents the parasite is expelled and in humans it can remain hidden for decades. Therefore, it is recommended that these experiments be studied in other models, including humans.

REFERENCES

AHMAD, Arine Fadzlun; HADIP, Faizah; NGUI, Romano; LIM, Yvonne A. L.; MAHMUD, Rohela. Serological and molecular detection of *Strongyloides stercoralis* infection among an Orang Asli community in Malaysia. **Parasitology Research**, [S. l.], v. 112, n. 8, p. 2811–2816, 2013. DOI: 10.1007/s00436-013-3450-z.

AMPANOZI, Garyfalia; KRINKE, Eileen; LABERKE, Patrick; SCHWEITZER, Wolf; THALI, Michael J.; EBERT, Lars C. Comparing fist size to heart size is not a viable technique to assess cardiomegaly. **Cardiovascular Pathology**, [S. l.], v. 36, p. 1–5, 2018. DOI: 10.1016/j.carpath.2018.04.009. Disponível em: <https://doi.org/10.1016/j.carpath.2018.04.009>.

ANJOS-RAMOS, L.; GAMA, L. A.; MATI, V. L. T.; CORÁ, L. A.; FUJIWARA, R. T.; AMERICO, M. F. Evaluation of gastrointestinal transit after infection with different loads of *Strongyloides venezuelensis* in rats. **Acta Tropica**, [S. l.], v. 156, p. 43–47, 2016. a. DOI: 10.1016/j.actatropica.2015.12.010. Disponível em: <http://dx.doi.org/10.1016/j.actatropica.2015.12.010>.

ANJOS-RAMOS, L.; GAMA, L. A.; MATI, V. L. T.; CORÁ, L. A.; FUJIWARA, R. T.; AMERICO, M. F. Evaluation of gastrointestinal transit after infection with different loads of *Strongyloides venezuelensis* in rats. **Acta Tropica**, [S. l.], v. 156, 2016. b. DOI: 10.1016/j.actatropica.2015.12.010.

BEKNAZAROVA, Meruyert; WHILEY, Harriet; ROSS, Kirstin. Strongyloidiasis: A disease of socioeconomic disadvantage. **International Journal of Environmental Research and Public Health**, [S. l.], v. 13, n. 5, 2016. DOI: 10.3390/ijerph13050517.

BELINELO, V. J.; GOUVÊIA, M. I.; COELHO, M. P.; ZAMPROGNO, A. C.; FIANCO, B. A.; OLIVEIRA, L. G. A. Enteroparasitas em hortaliças comercializadas na cidade de São Mateus, ES, Brasil. **Arquivos de Ciência da Saúde Unipar, Umuarama**, [S. l.], v. 13, n. 1, p. 33–36, 2009.

BEN SHELDON. Book Reviews Host Parasite Evolution : General. [S. l.], v. 14, n. 2, p. 1998, 1998.

BETHONY, Jeff; BROOKER, Simon; ALBONICO, Marco; GEIGER, Stefan M.; LOUKAS, Alex; DIEMERT, David; HOTEZ, Peter J. Soil-transmitted helminth infections : ascariasis , trichuriasis , and hookworm. **The Lancet**, [S. l.], v. 367, p. 1521–1532, 2006.

BETTS, A.; GRAY, C.; ZELEK, M.; MACLEAN, R. C.; KING, K. C. High parasite diversity accelerates host adaptation and diversification. **Science**, [S. l.], v. 360, n. 6391, p. 907–911, 2018. DOI: 10.1126/science.aam9974.

BOGAN, THE LATE J. A.; MCKELLAR, Q. A. The pharmacodynamics of ivermectin in sheep and cattle. **Journal of Veterinary Pharmacology and Therapeutics**, [S. l.], v. 11, n. 3, p. 260–268, 1988. DOI: 10.1111/j.1365-2885.1988.tb00151.x.

BRELOER, MINKA; ABRAHAM, DAVID. Strongyloides infection in rodents: immune response and immune regulation. **Parasitology**, [S. l.], v. 144, n. 03, p. 295–315, 2017. DOI: 10.1017/S0031182016000111. Disponível em: https://www.cambridge.org/core/product/identifider/S0031182016000111/type/journal_article.

BUCK, J. C.; WEINSTEIN, S. B.; YOUNG, H. S. Ecological and Evolutionary Consequences of Parasite Avoidance. **Trends in Ecology and Evolution**, [S. l.], v. 33, n. 8, p. 619–632, 2018. DOI: 10.1016/j.tree.2018.05.001. Disponível em: <https://doi.org/10.1016/j.tree.2018.05.001>.

CABRAL, Anna Caryna; IÑIGUEZ, Alena Mayo; MORENO, Taiza; BÓIA, Marcio Neves; CARVALHO-COSTA, Filipe Anibal. Clinical conditions associated with intestinal strongyloidiasis in Rio de Janeiro, Brazil. **Revista da Sociedade Brasileira de Medicina Tropical**, [S. l.], v. 48, n. 3, p. 321–325, 2015. DOI: 10.1590/0037-8682-0019-2015.

CANGA, Aránzazu González; PRIETO, Ana M. Sahagú.; DIEZ LIÉBANA, M. José; MARTÍNEZ, Nélica Fernández; SIERRA VEGA, Matilde; GARCÍA VIEITEZ, Juan J. The pharmacokinetics and interactions of ivermectin in humans - A mini-review. **AAPS Journal**, [S. l.], v. 10, n. 1, p. 42–46, 2008. DOI: 10.1208/s12248-007-9000-9.

DREW, Georgia C.; STEVENS, Emily J.; KING, Kayla C. Microbial evolution and transitions along the parasite–mutualist continuum. **Nature Reviews Microbiology**, [S. l.], v. 19, n. 10, p. 623–638, 2021. DOI: 10.1038/s41579-021-00550-7. Disponível em: <http://dx.doi.org/10.1038/s41579-021-00550-7>.

GIUNCHETTI, Rodolfo Cordeiro; MARTINS-FILHO, Olindo Assis; CARNEIRO, Cláudia Martins; MAYRINK, Wilson; MARQUES, Marcos José; TAFURI, Washington Luiz; CORRÊA-OLIVEIRA, Rodrigo; REIS, Alexandre Barbosa. Histopathology, parasite density and cell phenotypes of the popliteal lymph node in canine visceral leishmaniasis. **Veterinary Immunology and Immunopathology**, [S. l.], v. 121, n. 1–2, p. 23–33, 2008. DOI: 10.1016/j.vetimm.2007.07.009.

GUZZO, Cynthia A.; FURTEK, Christine I.; PORRAS, Arturo G.; CHEN, Cong; TIPPING, Robert; CLINESCHMIDT, Coleen M.; SCIBERRAS, David G.; HSIEH, John Y. K.; LASSETER, Kenneth C. Safety, tolerability, and pharmacokinetics of escalating high doses of ivermectin in healthy adult subjects. **Journal of Clinical Pharmacology**, [S. l.], v. 42, n. 10, p. 1122–1133, 2002. DOI: 10.1177/009127002401382731.

HERNÁNDEZ-CHAVARÍA, Francisco; AVENDAÑO, Leticia. A Simple Modification of the Baermann Method for Diagnosis of Strongyloidiasis. **Memorias do Instituto Oswaldo Cruz**, [S. l.], v. 96, n. 6, p. 805–807, 2001. DOI: 10.1590/S0074-02762001000600011.

IRIEMENAM, Nnaemeka C.; SANYAOLU, Adekunle O.; OYIBO, Wellington A.; FAGBENRO-BEYIOKU, Adetayo F. Strongyloides stercoralis and the immune response. **Parasitology International**, [S. l.], v. 59, n. 1, p. 9–14, 2010. DOI: 10.1016/j.parint.2009.10.009. Disponível em: <http://dx.doi.org/10.1016/j.parint.2009.10.009>.

KNOPP, Stefanie *et al.* Diagnostic accuracy of Kato-Katz, FLOTAC, Baermann, and PCR methods for the detection of light-intensity hookworm and Strongyloides stercoralis infections in Tanzania. **American Journal of Tropical Medicine and Hygiene**, [S. l.], v. 90, n. 3, p. 535–545, 2014. DOI: 10.4269/ajtmh.13-0268.

MARRA, Nelson Mendes; CHIUSO-MINICUCCI, Fernanda; MACHADO, Gabriel Capella; ZORZELLA-PEZAVENTO, Sofia Fernanda Gonçalves; FRANÇA, Thaís Graziela Donegá; ISHIKAWA, Larissa Lumi Watanabe; AMARANTE, Alessandro F. T.; SARTORI, Alexandrina; AMARANTE, Mônica R. V. Migratory route of Strongyloides venezuelensis in Lewis rats: Comparison of histological analyses and PCR. **Experimental Parasitology**, [S. l.], v. 127, n. 2, p. 334–339, 2011. a. DOI: 10.1016/j.exppara.2010.08.006. Disponível em: <http://dx.doi.org/10.1016/j.exppara.2010.08.006>.

MARRA, Nelson Mendes; CHIUSO-MINICUCCI, Fernanda; MACHADO, Gabriel Capella; ZORZELLA-PEZAVENTO, Sofia Fernanda Gonçalves; FRANÇA, Thaís Graziela Donegá; ISHIKAWA, Larissa Lumi Watanabe; AMARANTE, Alessandro F. T.; SARTORI, Alexandrina; AMARANTE, Mônica R. V. Migratory route of Strongyloides venezuelensis in Lewis rats: Comparison of histological analyses and PCR. **Experimental Parasitology**, [S. l.], v. 127, n. 2, p. 334–339, 2011. b. DOI: 10.1016/j.exppara.2010.08.006.

MENDONÇA, Jalvita C.; GAMA, Loyane A.; HAUSCHILDT, Andrieli T.; CORÁ, Luciana A.; AMÉRICO, Madileine F. Gastrointestinal effects of ivermectin treatment in rats infected with Strongyloides venezuelensis. **Acta Tropica**, [S. l.], v. 194, n. March, p. 69–77, 2019. DOI: 10.1016/j.actatropica.2019.03.024. Disponível em: <https://doi.org/10.1016/j.actatropica.2019.03.024>.

MØLLER, Anders Pape. A review of developmental instability, parasitism and disease infection, genetics and evolution. **Infection, Genetics and Evolution**, [S. l.], v. 6, n. 2, p. 133–140, 2006. DOI: 10.1016/j.meegid.2005.03.005.

OKTAR, Nezhik; OZER, Haluk; DEMIRTAS, Eren. Central nervous system strongyloides stercoralis. a case report. **Turkish Neurosurgery**, [S. l.], v. 30, n. 5, p. 776–779, 2020. DOI: 10.5137/1019-5149.jtn.22886-18.2.

OLSEN, Annette *et al.* Strongyloidiasis - the most neglected of the neglected tropical diseases? **Transactions of the Royal Society of Tropical Medicine and Hygiene**, [*S. l.*], v. 103, n. 10, p. 967–972, 2009. DOI: 10.1016/j.trstmh.2009.02.013.

POULIN, Robert; THOMAS, F. Phenotypic variability induced by parasites: Extent and evolutionary implications. **Parasitology Today**, [*S. l.*], v. 15, n. 1, p. 28–32, 1999. DOI: 10.1016/S0169-4758(98)01357-X.

REYES, Felix; SINGH, Navneet; ANJUMAN-KHURRAM, Nigar; LEE, Jihae; CHOW, Lillian. Strongyloides Hyperinfection Syndrome causing fatal meningitis and septicemia by *Citrobacter koseri*. **IDCases**, [*S. l.*], v. 10, n. August, p. 102–104, 2017. DOI: 10.1016/j.idcr.2017.09.005. Disponível em: <http://dx.doi.org/10.1016/j.idcr.2017.09.005>.

RIVERO, Juan C.; INOUE, Yoichi; MURAKAMI, Noboru; HORII, Yoichiro. Age- and sex-related changes in susceptibility of wistar rats to *Strongyloides venezuelensis* infection. **Journal of Veterinary Medical Science**, [*S. l.*], v. 64, n. 6, p. 519–521, 2002. DOI: 10.1292/jvms.64.519.

ROSSETTO, Anna; BACCARANI, Umberto; LORENZIN, Dario; RISALITI, Andrea; VIALE, Pierluigi; BRESADOLA, Vittorio; ADANI, Gian Luigi. Case Report Disseminate Fungal Infection after Acute Pancreatitis in a Simultaneous Pancreas-Kidney Recipient. [*S. l.*], v. 2010, p. 10–12, 2010. DOI: 10.1155/2010/898245.

SATOU, Tadaaki; KOGA, Masataka; KOIKE, Kazuo; TADA, Isao; NIKAIDO, Tamotsu. Nematocidal activities of thiabendazole and ivermectin against the larvae of *Strongyloides ratti* and *S. venezuelensis*. **Veterinary Parasitology**, [*S. l.*], v. 99, n. 4, p. 311–322, 2001. DOI: 10.1016/S0304-4017(01)00472-1.

SIDDIQUI, Afzal A.; BERK, Steven L. Diagnosis of *Strongyloides stercoralis* infection. **Clinical Infectious Diseases**, [*S. l.*], v. 33, n. 7, p. 1040–1047, 2001. DOI: 10.1086/322707.

SIECK, Gary C. Physiology in perspective: Anatomy and physiology—structure and function in biology. **Physiology**, [*S. l.*], v. 34, n. 6, p. 379–380, 2019. DOI: 10.1152/physiol.00029.2019.

SOUSA-RIBEIRO, C.; TAVORE, L. N. C.; ANJOS-RAMOS, L. *Strongyloides venezuelensis* infection augments arterial blood pressure in male wistar rats. **Acta Tropica**, [*S. l.*], v. 190, 2019. DOI: 10.1016/j.actatropica.2018.12.007.

TAKAMURE, A. Migration route of *Strongyloides venezuelensis* in rodents. **International Journal for Parasitology**, [*S. l.*], v. 25, n. 8, p. 907–911, 1995.

THOMAS B. NUTMAN. Human infection with *Strongyloides stercoralis* and other related *Strongyloides* species. **Parasitology**, [*S. l.*], v. 144, n. 3, p. 263–273, 2017. DOI:

10.1016/j.physbeh.2017.03.040.

TRACHTENBERG, Barry H.; HARE, Joshua M. Inflammatory cardiomyopathic syndromes. **Circulation Research**, [S. l.], v. 121, n. 7, p. 803–818, 2017. DOI: 10.1161/CIRCRESAHA.117.310221.

TRAILOVIĆ, Saša M.; NEDELJKOVIĆ, Jelena Trailović. Central and peripheral neurotoxic effects of ivermectin in rats. **Journal of Veterinary Medical Science**, [S. l.], v. 73, n. 5, p. 591–599, 2011. DOI: 10.1292/jvms.10-0424.

UTKUALP, Nevin; ERCAN, Ilker. Anthropometric measurements usage in medical sciences. **BioMed Research International**, [S. l.], v. 2015, p. 7, 2015. DOI: 10.1155/2015/404261.

VENNERVALD, B. J.; POLMAN, K. Helminths and malignancy. **Parasite Immunology**, [S. l.], v. 31, n. 11, p. 686–696, 2009. DOI: 10.1111/j.1365-3024.2009.01163.x.

VINEY, Mark; KIKUCHI, Taisei. Strongyloides ratti and S. venezuelensis - Rodent models of Strongyloides infection. **Parasitology**, [S. l.], v. 144, n. 3, p. 285–294, 2017. DOI: 10.1017/S0031182016000020.

YASUDA, Koubun; MATSUMOTO, Makoto; NAKANISHI, Kenji. Importance of both innate immunity and acquired immunity for rapid expulsion of S. venezuelensis. **Frontiers in Immunology**, [S. l.], v. 5, n. MAR, p. 1–5, 2014. DOI: 10.3389/fimmu.2014.00118.

ZAHA, O; HIRATA, T, KINJO, F; SAITO, A. Strongyloidiasis-Progress in Diagnosis and Treatment. **Internal Medicine**, [S. l.], v. 39, n. 9, p. 695–700, 2000.

CONTRIBUTION OF AUTHORSHIP

Anna Júlia Fernandes Figueiredo: Carried out the experiments and organized the resulting data.

Flávia da Silva Resende: Assisted in carrying out the experiments and organizing the results, as well as writing the article.

Vitor Luís Tenório Mati: Contributed to the analysis of the results and the composition of the article.

Luana Anjos-Ramos: Devised the project and oversaw the experimental process. Also analyzed the results and prepared the manuscript.